

HRCT Chest

**Dr. VENKATRAMAN.I., MDRD, ASSOCIATE
PROFESSOR DR.POONAM.C.,
MDRD RESIDENT
DR.SYEDHA FARIHEEN., MDRD RESIDENT.
DR.NIRANJAN.K., MDRD RESIDENT.**

**Department of Radiology, Sree Balaji
Medical College and Hospital, Chennai**



Discovery Publications

**No. 9, Plot,1080A, Rohini Flats, Munusamy Salai,
K.K.Nagar West, Chennai - 78. Tamilnadu, India.**

Mobile: +91 99404 46650

HRCT Chest

**Dr. VENKATRAMAN.I., MDRD, ASSOCIATE
PROFESSOR DR.POONAM.C., MDRD
RESIDENT
DR.SYEDHA FARIHEEN., MDRD RESIDENT.
DR.NIRANJAN.K., MDRD RESIDENT.©**

First Edition: April - 2022

ISBN: 978-93-94762-31-2

Pages 42

Print in India

Rs. 350

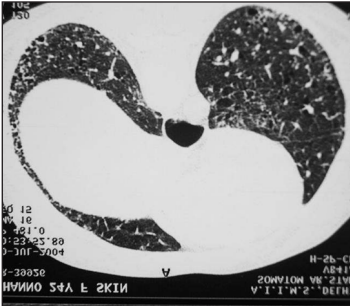Discovery Publications

No. 9, Plot, 1080A, Rohini Flats, Munusamy Salai,
K.K.Nagar West, Chennai - 78. Tamilnadu, India.

discoverybookpalace@gmail.com

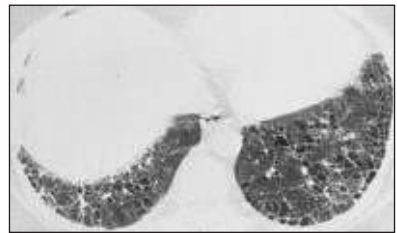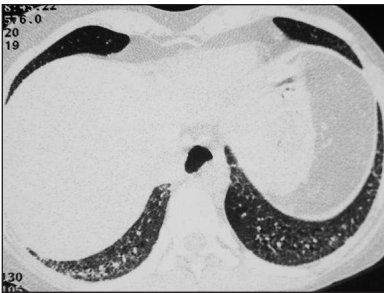WWW.DISCOVERYBOOKPALACE.COM

Progressive Systemic Sclerosis

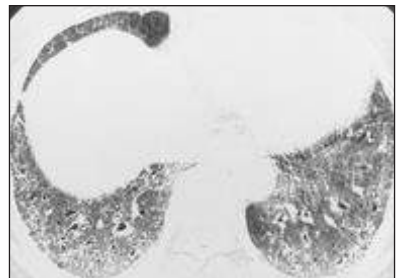


- ✓ GGO/consolidation - interstitial pneumonitis
- ✓ Fibrosis
- ✓ Lower lobes, peripheral/subpleural and posterior distribution
- ✓ Small centrilobular nodules (follicular bronchiolitis)
- ✓ Pleural effusion or UIP thickening

Progressive Systemic Sclerosis



UIP PATTERN



NSIP PATTERN

CONCLUSION

- ✓ The Imaging Of Dild Begins **With A Cxr**
- ✓ **Hrct** Is The **Best Imaging Tool** For Dild
- ✓ Vs Cxr Is **More Reproducible ,Comparable And Less Subjective**
- ✓ It Helps To Detect And Assess Disease,To Predict And Assess Response To Therapy,To Select Type And Site Of Biopsy
- ✓ **MdHrct** Imaging Allows Multiplanar And Complete Volumetric Imaging