



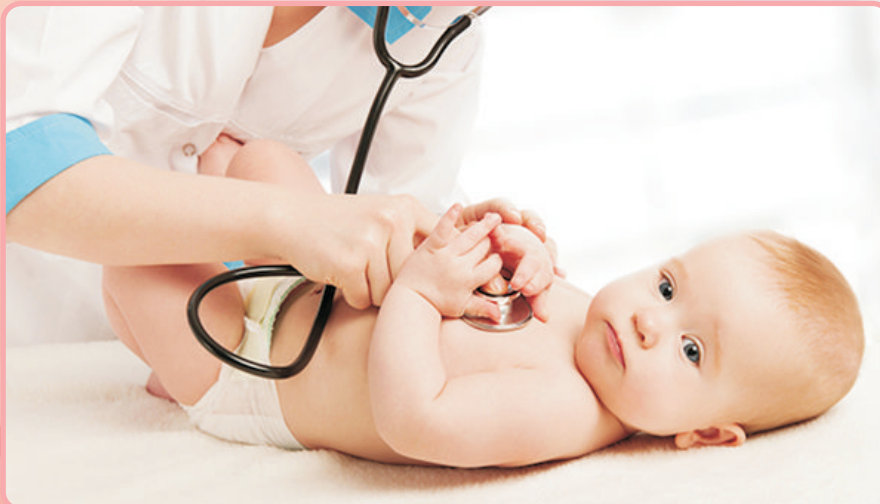**Sree Balaji Medical College & Hospital**  
Bharath Institute of Higher Education & Research  
**International Conference in Paediatrics**

**"BALPEDICON - 2021"**

**CONFERENCE PROCEEDINGS**

**April 29<sup>th</sup> & 30<sup>th</sup>, 2021**

***Theme: Quality Care for Better Child Survival & Beyond***



***Editors***

**Dr. S. Sundari**  
Professor and Head

**Dr. R. Somasekar**  
Professor

**Dr. Shanthi Ramesh**  
Professor  
Department of Paediatrics  
Sree Balaji Medical College & Hospital

***Organised by***

Department of Paediatrics  
**Sree Balaji Medical College & Hospital**  
Chromepet, Chennai - 600 044.



**Sree Balaji Medical College & Hospital**

**Bharath Institute of Higher Education & Research**

**International Conference in Paediatrics**

**BALPEDICON 2021**

**CONFERENCE PROCEEDINGS**

***Theme: Quality Care for Better Child Survival & Beyond***

**April 29<sup>th</sup> & 30<sup>th</sup>, 2021**

*Editors*

Dr. S. Sundari

*Professor and Head*

Dr. R. Somasekar

*Professor*

Dr. Shanthi Ramesh

*Professor*

Department of Paediatrics

Sree Balaji Medical College & Hospital

*Organised by*

**Department of Paediatrics**

**Sree Balaji Medical College & Hospital**

Chromepet, Chennai - 600044.

## Nevus Sebaceous of Jadassohn

**Dr. Kavya Vaishali<sup>1</sup>, Dr. Ramya R<sup>2</sup>, Dr. Sundari S<sup>3</sup>**

*<sup>1</sup>Junior Resident, <sup>2</sup>Assistant Professor, <sup>3</sup>HOD and Professor*

*Department of Paediatrics, Sree Balaji Medical College and Hospital*


---

**Introduction:** Nevus sebaceous is a benign hamartoma of the skin, characterised by hyperplasia of the epidermis, immature hair follicles, sebaceous and apocrine glands. Lesions are usually present at birth and appear as waxy, yellow-orange or tan, hairless plaques. During puberty the growths may develop secondary neoplasms within them.

**Case Report:** We report a 14 year old girl presented with raised pigmented lesions over the right of scalp. on examination soft, cereberi form and well demarcated nodular plaque was present over the scalp. X-ray skull CT brain was done to rule out bony extensions and intracranial communications Histopathological examination was done and diagnosis of nevus sebaceous was made and full thickness excision was done.

**Keywords:** *nevus sebaceous, hyperplasia, excision*

-----



## Sree Balaji Medical College & Hospital

*Published by*

**Aksharaa Muthra Aalayam Pvt., Ltd.**

No.441/303, Anna Salai, Teynampet, Chennai-18. Tamilnadu, India

Ph. 044 - 24364303. Cell: 9282134542,

E-mail: [murali.aks@gmail.com](mailto:murali.aks@gmail.com), Website: [aksharaa.co.in](http://aksharaa.co.in)

ISBN: 978-93-91255-79-4



9 789391 255794