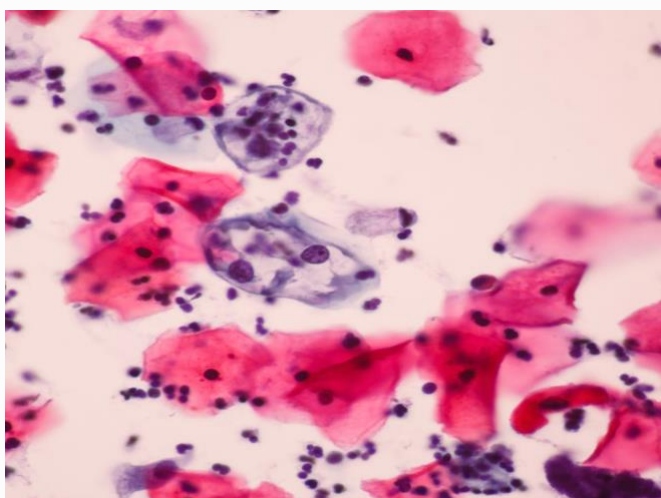




# **SREE BALAJI MEDICAL COLLEGE AND HOSPITAL**

## **DEPARTMENT OF PATHOLOGY**

### **CHANGES IN CONVENTIONAL AND LIQUID BASED CYTOLOGY PAP SMEAR IN VARIOUS CERVICAL LESIONS**



**Dr. Vinutha Gali**

Assistant Professor

Department Of Pathology

**Dr. Gayathri**

2<sup>nd</sup> yr PostGraduate

Department Of Pathology

## INDEX:

S.no	Topics	Page no
1.	Introduction	3
2.	Screening guidelines	6
3.	Sampling and preparation method	7
4.	Pap smear types	9
5.	Pap staining method	18
6.	Normal cells in a Pap smear	20
7.	The 2014 Bethesda System	31
8.	Ancillary testing	60
9.	Computer assisted interpretation	62

## References:

1. Cytology Diagnostic Principles and Clinical Correlates; Fifth Edition by Edmund S. Cibas, MD
2. The Bethesda System for Reporting Cervical Cytology Definitions, Criteria and explanatory notes; Third Edition
3. Singh A, Joshi C, Kujur P, Chandrakar K, Shrivastava S. Liquid-based Cytology versus Conventional Cytology for Evaluation of Cervical Cytology in a Tertiary Care Center of Chhattisgarh. IJSS. 2016 Dec 1;4(9):161-7.
4. Chandrasekhar V, Krishnamurti C. George Papanicolaou (1883–1962): Discoverer of the Pap Smear. The Journal of Obstetrics and Gynecology of India. 2018 Jun 1;68(3):232-5.
5. Koss' Diagnostic Cytology; fifth edition.