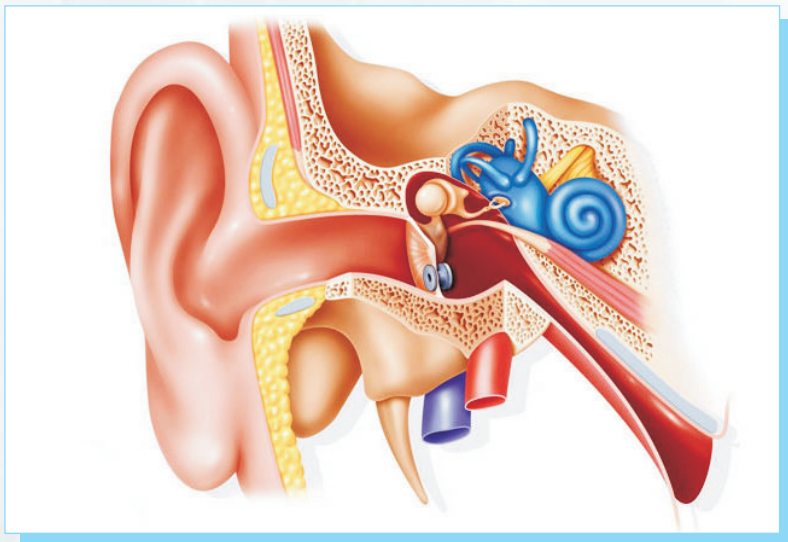


# Clinical Manual of ENT



*Author*

**Dr. MK Rajasekar MS, DLO**

*Professor and Head*

*Department of ENT, Head and Neck Surgery  
Sree Balaji Medical College and Hospital  
Bharath University, Chennai, Tamil Nadu*

*Co-Author*

**Dr. K.R Muralidharan**

*Junior Resident*

*Department of ENT*

*Sree Balaji Medical College and Hospital  
Bharath University, Chennai, Tamil Nadu*

*Published by*

**Department of ENT**

**Sree Balaji Medical College & Hospital  
Bharath Institute of Higher Education & Research (BIHER)  
Chromepet, Chennai - 600044, Tamilnadu, India**



# Clinical Manual of ENT

*Author*

**Dr. MK Rajasekar MS, DLO**

*Professor and Head*

*Department of ENT, Head and Neck Surgery*

*Sree Balaji Medical College and Hospital*

*Bharath University, Chennai, Tamil Nadu*

*Co-Author*

**Dr. K.R Muralidharan**

*Junior Resident*

*Department of ENT*

*Sree Balaji Medical College and Hospital*

*Bharath University, Chennai, Tamil Nadu*



Department of ENT  
Sree Balaji Medical College & Hospital  
Bharath Institute of Higher Education & Research (BIHER)  
Chromepet, Chennai - 600044, Tamilnadu, India



7. CSOM-Both mastoid lateral view

Laws view - X-ray beam projected 15 cephalocaudal

Schuller's view – X-ray 30 to the sagittal plane

Stenver's view- Long axis of petrous bone parallel to the film

8. Adenoids – Soft tissue lateral view lateral view of nasopharynx

9. Nasopharyngeal carcinoma -Lateral view

10. Nasopharynx & angiofibroma – Carotid angiogram (MRI)

11. Nasopharynx & hypopharynx – Lateral view

12. Barium swallow – pharyngeal pouch, oesophageal web, hypopharyngeal tumour, pressure form without by a thyroid swelling, cervical osteophyte

13. Lakyngecele ]- CXR with neck with & without Valsalva manoeuvre- AP

14. T.B Larynx – CXR-PA view


15. Parotid calculi- Lateral

16. Sub mandibular calculi – open mouth – AP

17. Sub lingual calculi – open mouth – AP

18. Internal auditory canal – Towne's view





**Sree Balaji Medical College & Hospital**

*Typeset & Printed by*

**Aksharaa Muthra Aalayam Pvt., Ltd.,**

No.441/303, Anna Salai, Teynampet, Chennai-18. Tamilnadu, India

Ph. 044 - 45080083. Cell: 9282134542

E-mail: murali.aks@gmail.com

**ISBN: 978-93-94609-07-5**



9 789394 609075