

**Department of Dermatology, Venereology and
Leprosy Sree Balaji Medical College and Hospital,
Chennai**

Symposium(22/02/24)

**1.DR ASHNA(JUNIOR RESIDENT)-PSORIASIFORM
REACTION PATTERNS.**

2.DR SANTHOSH- INTERFACE DERMATITIS


3.DR NOURIN – GIANT CELLS

The first presentation was by Dr ashna on psoriasiform reaction patterns. Psoriasiform reaction pattern is a histological term given to dermatological conditions showing epidermal hyperplasia and regular elongation of rete ridges . The major psoriasiform dermatoses are psoriasis, psoriasiform keratosis , pityriasis rubra pilaris , parapsoriasis , Reiters disease . Other disorders like pellagra, ILVEN also show psoriasiform hyperplasia . Other features of exocytosis, parakeratosis , dilation of the dermal capillaries and perivascular infiltration are noted

It was followed by discussion of lichenoid dermatitis by dr.santhosh s, the difference between interface dermatitis and lichenoid dermatitis were explained, the types of lichenoid dermatitis were explained, the pathology and different lichenoid dermatitis patterns of each conditions were explained with diagramatic representation.

It was followed by the last presentation on Giant cells by Dr Nourin.Giant cells are multinucleated cells which are formed by fusion Macrophages, monocytes, epidermal cells, melanocytes etc. Giant cells can be physiological and pathology.The different types of giant cells with diagrams were explained. The pathogenesis of the formation of giant cells were also explained andThe different conditions where these giant cells are seen were also discussed

Towards the end, Dr sukanya prof dept of DVL gave her views on psoriasiform reaction patterns,interface dermatitis and giant cells.The session was then concluded



LICHENOID DERMATITIS

S. Corium
S. granulosum
S. spinulosum
S. basale

Papillary cell
Basal cell
DET
VASCULAR DEVELOPMENT
LYMPHOCYTES
INFLUX

ZIEHL-NEILSEN STAINING
Lentel

Morphea

LSEA
Thinning of rete ridges
follicular plugging
Apoptotic layer of basal layer

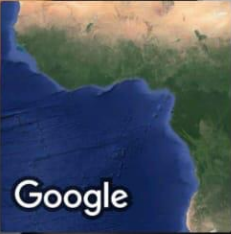PSORIASIFORM HYPERPLASIA

Hypokeratin
Parakeratosis
Munros microabscess
Spongiform pustule of Kojan
Elongation of rete ridges
Dilated dermal capillaries
Infiltrate
Club shaped Rete ridges

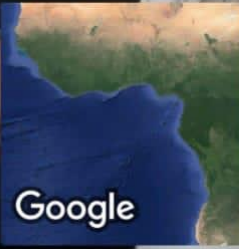
1) Psoriasis
2) PRP
3) Psoriasis
4) Psoriasis
5) LSC
6) PRP
7) Psoriasis

edema @ early stage
Inflammatory cell @ Psoriasis

GPS Map Camera



Chennai, Tamil Nadu, India
X43Q+QQR, Shankar Nagar, Chromepet, Chennai, Tamil Nadu 600044, India
Lat 12.954832°
Long 80.13942°
22/02/24 01:39 PM GMT +05:30



Chennai, Tamil Nadu, India
X43Q+QQR, Shankar Nagar, Chromepet, Chennai, Tamil Nadu 600044, India
Lat 12.954832°
Long 80.13942°
22/02/24 01:46 PM GMT +05:30

 **GPS Map Camera**

