

## RADIO PATH IDM(27/2/25)

TOPIC- Invasive carcinoma breast- Mucinous type

PRESENTER- Dr. Revathy

1. INVASIVE CARCINOMA BREAST- ,ER ,PR positive

HER2 neu- variable ,so advised to do FISH

2. In Mastectomy Specimen- DCIS component present

3. Solid,Cribriform,Comedo

4.  Any tumor showing special type >90% tumor are designated as pure special tumor

5.  If less than 90% they are designated as No special type

6. Three pillars for diagnosis- Physical Examination,Imaging,Cytology/Biopsy.

7. Self Examination of breast is must

8. To know about MOLECULAR CLASSIFICATION

LUMINAL A

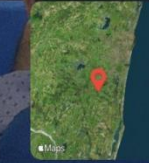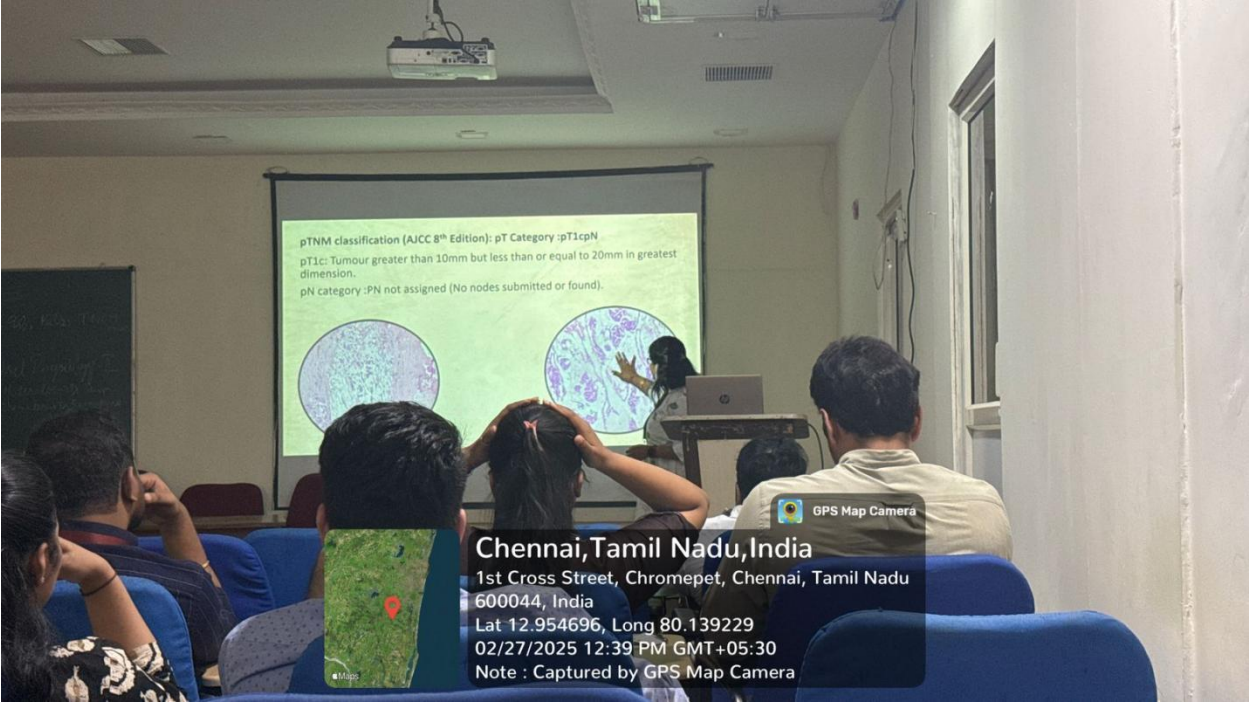
LUMINAL B

Her 2 Enriched

Basal like TNBC

9. Always use Two myoepithelial markers for confirmation

10. should not rely completely on negative myoepithelial markers ,but also to see H and E findings.



Chennai, Tamil Nadu, India  
1st Cross Street, Chromepet, Chennai, Tamil Nadu  
600044, India  
Lat 12.954696, Long 80.139229  
02/27/2025 12:39 PM GMT+05:30  
Note : Captured by GPS Map Camera